

**APPLICATIONS THE DRUG SLEZOVIT WITH A COMBINATION OF
RETINALAMINE IN RETINAL DYSTROPHY****Usmanova Tulganoy Jaloliddinovna**

Andijan State Medical Institute

<https://doi.org/10.5281/zenodo.7433267>

Abstract. The article explains the scientific significance of retinal dystrophy. An actual problem in ophthalmology at the present time is retinal dystrophy (DS). This is due to the progressive increase in the incidence of this pathology.

Key words: Retinal dystrophy, OCT, Goniolinsa.

**ПРИМЕНЕНИЕ ПРЕПАРАТА СЛЕЗОВИТ С КОМБИНАЦИЕЙ РЕТИНАЛАМИНА
ПРИ ДИСТРОФИИ СЕТЧАТКИ**

Аннотация. В статье объясняется научное значение дистрофии сетчатки. Актуальной проблемой офтальмологии в настоящее время является дистрофия сетчатки (ДС). Это связано с прогрессирующим ростом заболеваемости данной патологией.

Ключевые слова: дистрофия сетчатки, ОКТ, гониолинзы.

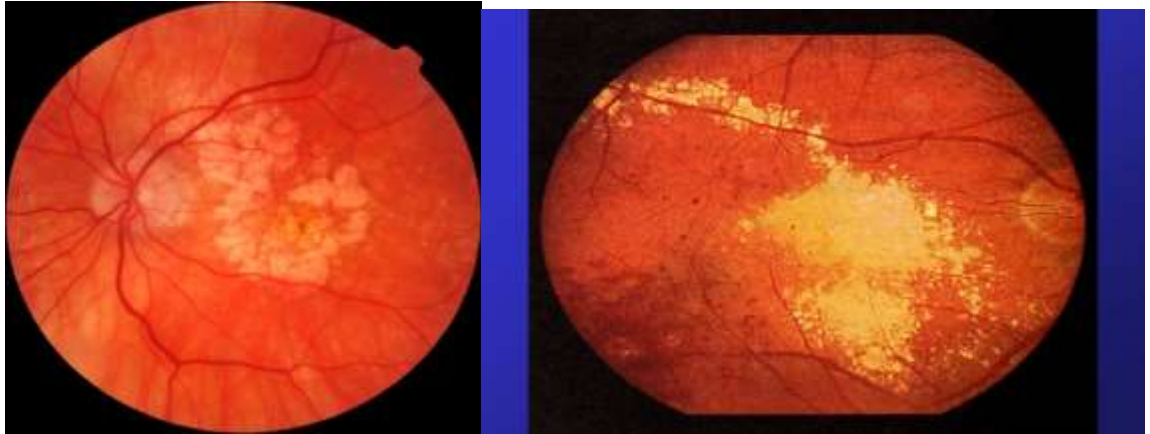
Retinal dystrophy is a fairly rare disease. It occurs in 1 out of 5.000 people, and there are about 100 million carriers of the defective retinitis gene. During the progression of this disease, the eye turns from a light-absorbing structure into a light-reflecting structure, which inevitably leads to blindness. Retinitis is more common in the male half of the population and can manifest itself both in childhood and more mature. According to statistics, the majority of patients with retinitis under the age of 20 retain the ability to read, and visual acuity exceeds 0.1; at the age of 45-50, visual acuity becomes below 0.1, and the ability to read is lost. The exact cause of the disease has not been established, but ophthalmologists name only versions of the development of retinal degeneration:

1. Sclerosis of the vascular membrane of the eye.
2. Disorders of the endocrine system with a lack of vitamin A.
3. Exposure to infections and toxins.
4. The state of the immune system.

Retinal dystrophy is a degenerative disorder on the inner lining of the eye. The retina itself has so-called rods, due to which the visual organ works correctly. With this pathology, their violation occurs. For this reason, a change in the retinal neuroepithelium, the pigment epithelium, is obtained. Dystrophic disorder is a dangerous and rare disease, as it can lead to blindness and disability. Retinal dystrophy is a degenerative disorder on the inner lining of the eye. The retina itself has so-called rods, due to which the visual organ works correctly. With this pathology, their violation occurs. For this reason, a change in the retinal neuroepithelium, the pigment epithelium, is obtained. Dystrophic disorder is a dangerous and rare disease, as it can lead to blindness and disability. Predisposing factors are: retinal vascular sclerosis - the capillary plate is broken here; violation of intrauterine development - bad habits, taking strong medications, stressful situations lead to a deviation in fetal growth; age - gradually the vessels wear out, the cells begin to die; pathological disorders in the endocrine system caused by a lack of vitamin A; brain injuries - which causes metabolism and changes in blood supply; weak immune system; toxic substances, radiation disrupt the structure of DNA.

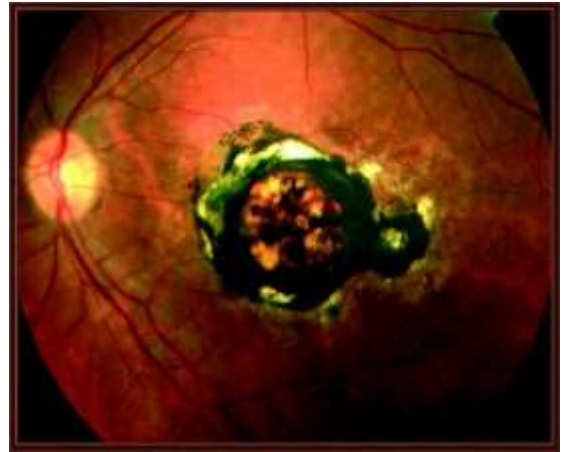
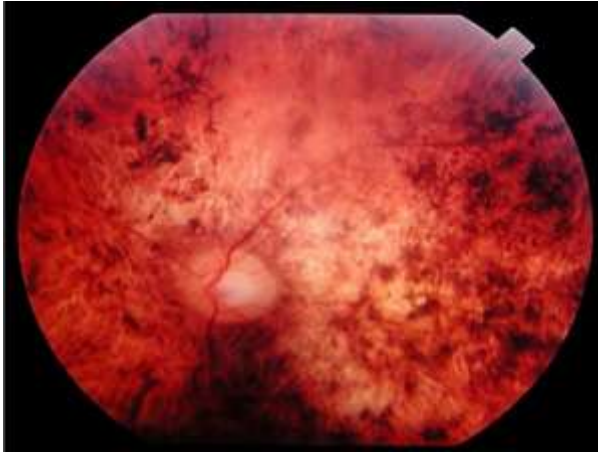
Types of dystrophy: Pigmented - vitamins and special gymnastics will help restore vision.

Dotted white - often leads to strabismus



Best - creates a veil before the eyes. Stargardt's spot dystrophy is a hereditary disease, vision loss occurs slowly. The severe course of the disease is dangerous by atrophy of the optic nerve, which subsequently develops blindness. What are the symptoms of retinal pigment degeneration that occurs sluggishly, without pronounced signs. This is the whole danger. The initial deviation signal is a decrease in a person's ability to recognize objects in a dimly lit space. In the case of a genetic factor, the disease manifests itself at a young age. What parents do not immediately pay attention to, believing that the baby is afraid of the dark.

Symptoms of retinal dystrophy: instant eye fatigue at night; weakening or absence of peripheral vision; movement coordination disorder while in a dark corridor, street; narrowing of the field of vision; inability to correctly distinguish a moving object from a resting one; violation of color recognition; formation of flies in front of the eyes. In the presence of such a clinical picture, it is important to contact an ophthalmologist in time. Slowing down of therapeutic actions is capable of progression of pathology and retinal detachment. How to diagnose First of all, the doctor asks the patient about the existing symptoms and their duration. The genetics of the patient is being carefully studied. Then the following diagnostic actions are performed: blood, urine analysis - with their help, the presence of infection, parasitic diseases, inflammatory process in the body is established; cancer markers for the absence of oncology are immediately studied; visual acuity check - special lenses, tables are used; electrophysiological examination - manipulation allows you to fairly assess the functionality of the retina; examination of the fundus - spots are carefully studied; the level of organ damage is determined by the presence of bone bodies, paling of the optic nerve disc is noted; color blindness test – if a person confuses colors in pictures, this is a sign of pigmented dystrophy; assessment of the patient's orientation in a poorly lit room.



Since there is no exact cause of retinal pigment degeneration, there is no definite treatment. However, there are supportive techniques, as a result of which it turns out to stop the progression of the disease. It has been clinically proven that taking Slezovit leads to a significant increase in the density of retinal pigment epithelium, which is necessary for the treatment and prevention of PDS. The composition of Slezovit includes vitamin composition B, A.S.E, zinc and taurine in the required concentrations. In a multicenter study, it was proved that the course intake of a combination of tears with lutein and antioxidants with has been proven to significantly increase the optical density of retinal dystrophy.

At the Department of Ophthalmology of the FUV Andijan State Medical Institute for more than 5 years, Slezovit and retinalamine have been successfully used in patients with various ophthalmological pathologies. The aim of this study was to study the clinical efficacy of Slezovit and retinalamine in patients with the initial form of retinal dystrophy.

Material and methods. 135 patients (85 women and 50 men) aged 18-56 years were under our supervision for 2 years. The patients were divided into 2 groups. The first group - the control group - consisted of 80 people with various etiologies of retinal dystrophy, who for various reasons did not receive any specific therapy for 6 months. The second group consisted of 55 people who received a course of standard conservative maintenance therapy for 10 days every 6 months: p / b injections of emoxypine, trental, i/ m injections of B vitamins, nicotinic acid, mildronate. After the end of the course of treatment, patients of this group were prescribed Slezovit 1 tablet 1 time a day for 1 month. Retinalamine 1.0 parabolbarno No. 10. Standard ophthalmological methods were used: visometry, ophthalmoscopy, perimetry, tonometry, retinal examination with gonioscope and OCT. Studies were conducted before the start of treatment and after 6 months.

The results of the study. Among the studied indicators of the functional state of the visual organ, the greatest dynamics was noted from the side of acuity and field of vision. The dynamics of the retina was judged on the basis of gonioscopy data. Before the start of treatment, patients of 1-2 groups had a loss of field of vision by $32 \pm 6\%$. In patients of the first (control) group, progressive deterioration of visual field parameters (central and paracentral scotoma) was noted throughout the study period. In patients of the second group, after a course of treatment, a slight decrease in central scotoma was detected. During the entire study period, the majority of patients had a stabilization of the visual field, and a decrease in central scotoma was noted in some patients.

Conclusions: Today, in many countries, issues of treatment of retinal pigment degeneration are being developed. Scientists are actively studying the functional anatomy and biology of the organs of vision, exchanging achievements in the field of neuro-ophthalmology,

improving methods of microsurgery and cell transplantation. All this makes the prospect of successful treatment of retinal degeneration quite real.

1. The use of the drug Slezovit and retinalamin in patients with initial retinal dystrophy as part of complex drug therapy for 3 months leads to stabilization of visual functions.

2. The use of the drug Slezovit for 3 months in patients with retinal dystrophy leads to a significant decrease in central scotoma, stabilization of visual functions.

3. The drug Slezovit can be recommended to patients with the initial form of retinal dystrophy, myopic chorioretinitis, macular degeneration, as an effective means of improving the visual functions of patients. Use the drug Slezovit should be 1 tablet 1 time per day in courses lasting at least 3 months.

REFERENCES

1. Bernstein P., Khachik F., Carvalho L. et al. //Exp.Eye.Res. - 2001- № 3- P. 215- 223.
2. Berendschot T.//Invest. Ophthalmol.Vis.Sci. - 2000. - Vol. 41, № 11. - P. 3322.
3. 3326.